



Heated Intraperitoneal Chemotherapy in Appendiceal Cancer Treatment

Robin Cianos, RN, OCN®, Sharon LaFever, MS, RN, AOCN®, and Nicole Mills, BSN, RN

Appendiceal cancer is rare and has been treated traditionally with repeated surgical debulking; however, cytoreductive surgery (CRS) with heated intraperitoneal chemotherapy (HIPEC) is becoming the preferred treatment modality because of improved survival. Nurses are responsible for knowing how to care for patients who are receiving or have received this treatment and need to be prepared to provide education on oncofertility. This case study illustrates the nursing implications of pregnancy and childbirth following CRS with HIPEC.

Robin Cianos, RN, OCN®, is a heated intraperitoneal chemotherapy coordinator and Sharon LaFever, MS, RN, AOCN®, is an oncology clinical nurse specialist, both at St. Agnes Hospital, and Nicole Mills, BSN, RN, is a nurse in the Department of Radiation Oncology at Johns Hopkins Hospital, all in Baltimore, MD. The authors take full responsibility for the content of the article. The authors did not receive honoraria for this work. No financial relationships relevant to the content of this article have been disclosed by the authors or editorial staff. Cianos can be reached at rcianos@stagnes.org, with copy to editor at CJONEditor@ons.org.

Digital Object Identifier: 10.1188/13.CJON.84-87

Heated intraperitoneal chemotherapy (HIPEC) is an increasingly popular treatment modality used internationally in combination with cytoreductive surgery (CRS) to treat intraperitoneal malignancies. CRS with HIPEC now is becoming the standard treatment regimen in the United States for appendiceal cancers (Sugarbaker, 2006). However, the effects of intraperitoneal chemotherapy on the reproductive organs in women receiving HIPEC have yet to be discovered fully. That is not a concern for many patients, as the ovaries often are removed during CRS because of their close proximity to the appendix (see Figure 1). As a result, pregnancy following CRS with HIPEC is rare. However, occasions exist in which ovary preservation is chosen, and the implications of this treatment on fertility have not been studied.

Appendiceal Cancer

Tumors of the appendix are relatively rare and comprise approximately 1% of

all colorectal cancer cases in the United States, or about 1,500 cases per year (Sugarbaker, 2006). The majority of those tumors are discovered incidentally in appendectomy specimens, after a computed tomography (CT) scan, or during surgical exploration for another diagnosis (Benedix et al., 2010; McGory, Maggard, Kang, O'Connell, & Ko, 2005). Patients most often present with appendicitis or increased abdominal girth; however, presentation can vary by gender, with men presenting with an enlarging hernia (inguinal or umbilical) and women presenting with an ovarian mass (Sugarbaker, 2009). The clinical presentation and progression of disease depends mainly on the histology of the tumor.

Cytoreductive Surgery

Staging is challenging because several histologic subtypes exist, with different survival outcomes. The subtypes and five-year disease-free survival rates are malignant carcinoid (93%), goblet cell carcinoid (81%), mucinous adenocarcinoma (58%), colonic-type adenocarcinoma (55%), and signet ring cell type (27%) (Turaga, Pappas, & Gamblin, 2012). Tumors with mucinous histology are the most prevalent and are further categorized into low grade (pseudomyxoma peritonei syndrome [PMP] is the most common) and high grade. Low-grade tumors do not require systemic chemotherapy but are most often treated with CRS and HIPEC. High-grade tumors, depending on histology, often require systemic chemotherapy before and after CRS and HIPEC; in the authors' practice, that process often is described to patients as a "sandwich approach."

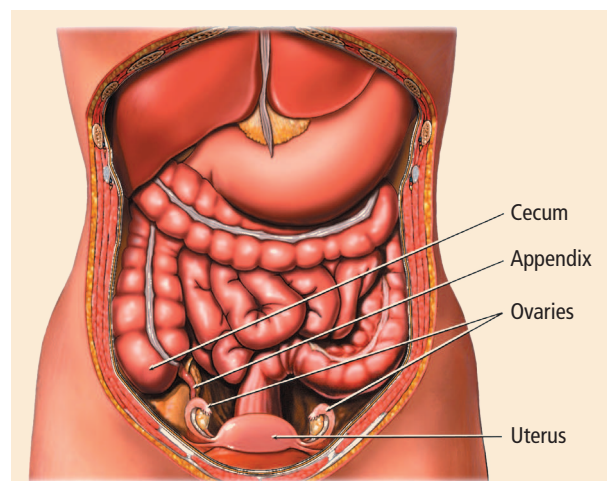


FIGURE 1. Anatomy of the Female Abdomen

Note. Medical illustration copyright © 2012 Nucleus Medical Media. All rights reserved. <http://www.nucleusinc.com>